

THE
Journal
OF
Nervous and Mental Disease

Original Articles

ON HERPETIC INFLAMMATIONS OF THE GENICULATE
GANGLION. A NEW SYNDROME AND ITS
COMPLICATIONS.*

By J. RAMSAY HUNT, M.D.,

OF NEW YORK.

CHIEF OF THE NEUROLOGICAL CLINIC AND INSTRUCTOR IN NERVOUS DISEASES
IN THE CORNELL UNIVERSITY MEDICAL COLLEGE.

(FROM THE PATHOLOGICAL LABORATORY OF THE CORNELL UNIVERSITY MEDICAL
COLLEGE.)

Under the general heading of herpetic inflammations of the geniculate ganglion of the facial nerve, I have brought together for the first time three separate groups of cases; each group presenting distinct and clearly defined characteristics, but showing various combinations and transition forms. Their union I believe constitutes a new and distinct clinical entity.

The pathology of this affection is identical with that of herpes zoster, of which it forms a part, the distinguishing features of the clinical picture depending entirely upon the ganglion involved and the nature of the structures surrounding it. Heretofore the only recognized seat of an herpetic inflammation on a cranial nerve was that of the Gasserian ganglion of the trifacial. Herpes zoster in the distribution of one or more of its branches was the result. I believe, however, that the geniculate ganglion situated in the depths of the internal auditory canal at the entrance to the Fallopiian aqueduct may be the seat of this specific inflammation. The peculiar situation of the ganglion within the confines of a bony canal and its immediate relationship to the facial and the

*Presented at the meeting of the American Neurological Association, June 4 and 5, 1906.

close proximity of the auditory nerve are responsible for the characteristic complex of symptoms which results.

As was long ago pointed out by Bärensprung and is now definitely established by the elaborate clinical and pathological researches of Head and Campbell, the primary or infectious form of herpes zoster is dependent upon a specific inflammation of one or more of the posterior spinal ganglia. Head suggested the name, posterior poliomyelitis for the affection, and certain points of resemblance were drawn between it and acute anterior poliomyelitis. The ganglia involved are swollen by the products of inflammation and by extravasation of blood, and in some cases even the sheath and nerve roots may be involved in the inflammatory process. In very rare instances the anterior or motor root, resting upon the sheath of the ganglion may be implicated and paralysis result.

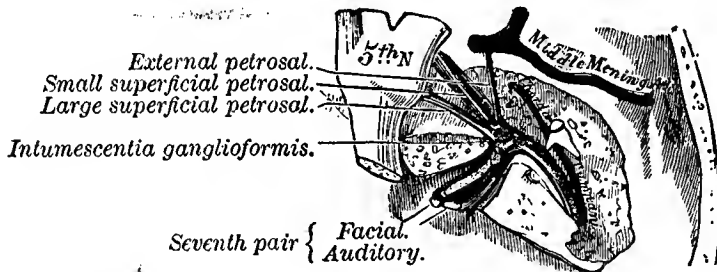


Fig. I.

The course and connections of the facial nerve in the temporal bone. (Gray's anatomy.)

Such paralytic complications are, however, extremely uncommon, and the total number of recorded cases is so small that they may be given in a few words. Herpetic inflammation of the Gasserian ganglion has given rise to palsies of the neighboring ocular nerves in 15 cases; in 12 cases the oculo-motor was the nerve affected, in two cases the trochlear and in one case the abducens. Paralytic complications of spinal zoster are recorded even less frequently. Arm palsies were observed in eight cases, to which I can add a personal observation, and a localized paralysis of the abdominal muscles in one case. Where the herpetic inflammation attacks the geniculate ganglion, palsies are of much

more frequent occurrence than in any other localization of the disease. I have collected 56 cases from the literature to which I can add 4 personal observations, making a total of 60 cases in which palsies accompanied the inflammation in this situation. This I would attribute to the peculiar location and relations of the ganglion involved.

Clinically the cases of geniculate herpes resolve themselves into three groups. The simplest expression of the disease is a herpes of the auricle and external auditory canal. *Within this skin area is to be found the zoster zone for the geniculate ganglion.* In another group of cases there is added to the aural herpes a paralysis of the facial nerve. This I explain by pressure of the inflamed ganglion or in some cases by a direct extension of the inflammation to the nerve. The most interesting, as well as the most severe, type of the disease occurs when the acoustic nerve is also involved. In this form there are with herpes auricularis and facial palsy, various auditory symptoms, ranging in severity from tinnitus aurium and diminution of hearing to the more severe forms of acoustic involvement as seen in Ménière's syndrome. In these cases I assume that the inflammatory process has extended to the auditory nerve which is enveloped in the same sheath, and courses in the same canal as the facial nerve.

Each of these groups has separately been the subject of careful study by many observers; but their intimate clinical relationship to one another, their common pathology and their common seat of origin, the geniculate ganglion of the facial nerve, has not heretofore been recognized.

I have already expressed my belief that the geniculate ganglion has its cutaneous representation and zoster zone in the auricle and external auditory canal, and that herpes zoster in this region may have facial and auditory complications. In regard to the distribution of the zoster I wish to lay especial stress upon this fact, that while these neural complications occur in auricular herpes, they also accompany herpes facialis, herpes occipitalis and cervicalis. It will be observed that in these forms of zoster, the herpes facialis and herpes occipito-collaris, the zoster zones lie immediately in front of and behind that which I have indicated as the geniculate zoster zone. Thus the Gasserian, geniculate and 2d and 3d cervical ganglia may be regarded as forming a

J. RAMSAY HUNT

ganglionic series or chain, their cutaneous zones corresponding to the face, ear, head and neck.

It is not difficult to find an explanation for the occurrence of neural complications (facial and auditory) in those forms of zoster in which the eruption is not in the auricle and therefore is not in the geniculate area. The pathology of herpes zoster is such that while the inflammation predominates or is centered chiefly in one ganglion, other ganglia immediately above and below this central focus may also show inflammatory changes, but in a lesser degree. In fact, a series of ganglia may show milder degrees of inflammation. So that while one ganglion may be regarded as the central focus, evidences of inflammation are not infrequently present in recent cases, in the ganglia immediately above and below, diminishing in intensity from the central lesion.

As the Gasserian, geniculate, and upper cervical ganglia form a continuous system of cutaneous zones, so they may be regarded as forming anatomically a ganglionic series. It is therefore quite natural that if the chief focus of inflammation is centered in the Gasserian, subsidiary inflammatory changes may occur in the other ganglia of this group, the geniculate, and the upper cervical. In such an event the presence of facial and auditory symptoms with herpes occipito-collaris or herpes facialis would be readily explained. As a further evidence of multiple involvement of this group of ganglia may be cited cases in which the zoster eruption covers two distinct and separate zoster zones.

An idea of the relative frequency of these neural complications and their associated herpetic eruptions may be obtained from the following statistics. In the 60 cases at my disposal for analysis, all had a facial palsy of the peripheral type. In 19 of these cases irritative or paralytic symptoms of acoustic origin were present. In 32 cases the cutaneous manifestation was herpes occipito-collaris, in 12 cases herpes facialis, in 12 cases herpes auricularis, in 3 cases a combined herpes auricularis and occipito-collaris, in one case herpes facialis and occipito-collaris combined. I may also add that I have found but one case of herpes zoster with an associated facial palsy in which the eruption was not facial, auricular, or occipito-cervical.

With these introductory remarks I will proceed to a more detailed description of the anatomy, pathology and symptomatology of the affection.

Anatomical Considerations.—Before proceeding to the clinical aspect of my subject, it is of great importance that certain facts pertaining to the anatomy of the facial nerve and its ganglion should be known. The facial nerve clinically is generally regarded as a motor nerve. This from the anatomical standpoint is not the case. Histological and embryological investigations during the past ten years have shown conclusively that the facial is a mixed nerve, possessing an afferent or sensory portion, which is the nerve of Wrisberg, and a ganglionic structure, the geniculate, analogous in structure to the spinal ganglia of the posterior

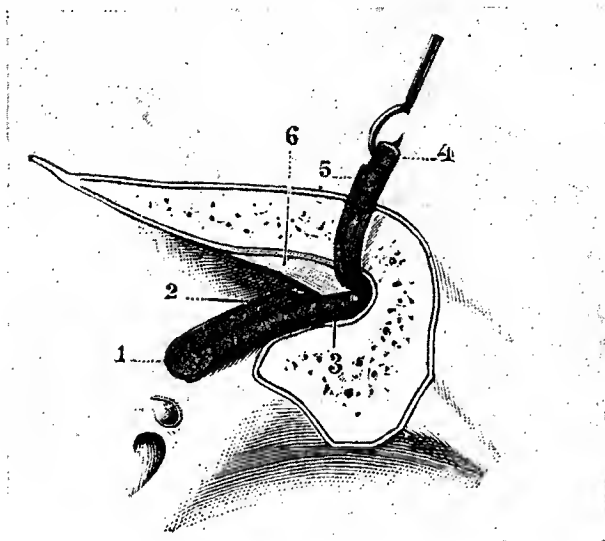


Fig. 2.

TESTUT.—The auditory nerve in the internal auditory canal. 1. Auditory nerve. 2. Cochlear-branch. 3. Vestibular-branch. 4. Facial. 5. Nerve of Wrisberg.

roots, the cell type of the geniculate corresponding exactly to that of the spinal and Gasserian ganglia.

The facial enters the internal auditory meatus in company with the acoustic and the nerve of Wrisberg. Within the auditory canal the 7th which is above rests in a slight concavity formed by the acoustic, the *pars intermedia* or nerve of Wrisberg lying between. All these nerve trunks are united and held together by a common sheath of connective tissue. At the bottom of the canal the acoustic divides into its cochlear and vestibular branches,

the nerve of Wrisberg and the facial entering the aqueduct of Fallopius. Immediately after its entrance the facial swells into the *intumescencia gangliiformis*, in which the nerve of Wrisberg takes its origin. From this point the facial nerve proper is continued to its peripheral distribution through the Fallopian aqueduct. As it lies in the entrance of the Fallopian aqueduct and the *Hiatus Fallopii*, the geniculate has important connections with other ganglia. It is connected with the spheno-palatine ganglion (Meckel's) through the great superficial petrosal nerve, and with

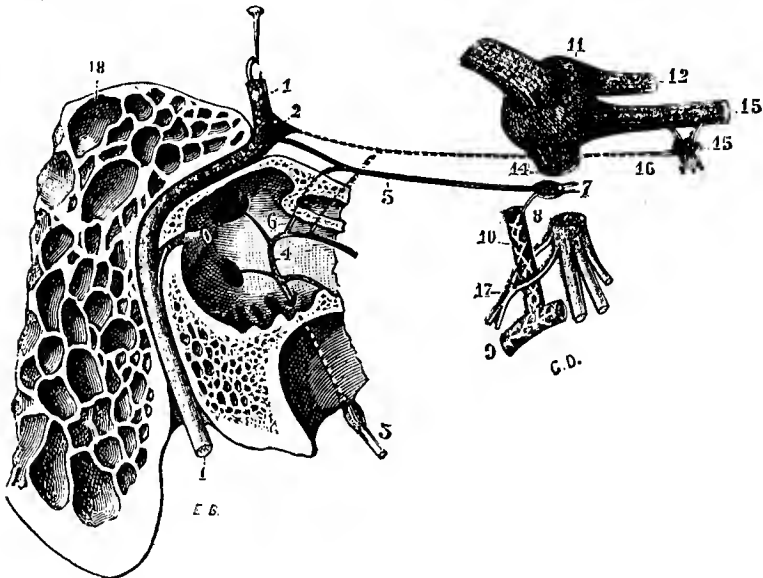


Fig. 3.

TESTUT'S ANATOMY.—The facial nerve, geniculate ganglion and relations with the otic. 1. Facial nerve. 2. Geniculate. 3. Glossopharyngeal. 4. Jacobson's nerve. 5. Small superficial petrosal. 6. Small deep petrosal. 7. Otic ganglion. 8. Sympathetic ramus. 10. Middle meningeal artery. 11. Gasserian ganglion. 12. Ophthalmic branch. 13. Superior maxillary. 14. Inferior maxillary. 15. Spheno-palatine ganglion. 16. Vidian nerve. 17. Auriculo-temporal nerve.

the otic ganglion (Arnold's) through the small superficial petrosal nerve. At their entrance into the medulla oblongata the 7th, 8th and *pars intermedia* have the following relations; the *pars intermedia* lies between the facial and the internal root of the acoustic. It sometimes joins one, sometimes the other of these two nerves as it enters the bulb, terminating in the *fasciculus solitarius* and the central gray column of the medulla. (Fig. 3.)

From this brief résumé of recognized and well founded facts it will be observed that my views regarding the affection under discussion finds only encouragement and support.

As the specific infection of herpes attacks only cells of the spinal ganglion type, the geniculate may very properly be brought within the sphere of its influence. Furthermore the intimate relations existing between the facial, the geniculate ganglion, and the terminal division of the acoustic would render all these structures liable to involvement when the seat of an inflammatory process; all the more because they are lodged in the depths of an osseous canal, within a common sheath, which would tend to resist expansion and increase the effect of pressure. (See Fig. 4.)

It may be added that the geniculate ganglion varies in size.




Fig. 4.

TESTUT.—Anastomoses of the facial and auditory nerves. 1. Facial. 2. Auditory. 3. Nerve of Wrisberg. 3'. Geniculate ganglion. 4. Internal anastomoses. 5. External anastomoses.

In some subjects it is scarcely visible to the naked eye; in others the swelling is double the caliber of the nerve. This may well have a certain influence in determining the severity of the case, anatomical peculiarities of the canal contributing.

The Zoster Zone for the Geniculate Ganglion.—Admitting the sensory nature of this ganglion, its analogy to a spinal ganglion and its probable involvement in cases of herpes zoster, it is still necessary to demonstrate the existence of a cutaneous area on the head or face to represent it. This area must be independent of other recognized zoster zones and in it should be found the zoster zone of the geniculate. This zone, I believe, is situated

within the auricle and external auditory canal. My argument bearing on this part of the subject is briefly as follows: The peripheral innervation of the external ear is effected through the fifth nerve, branches of the cervical plexus, and *the auricular branch of the vagus*. The anterior half of the auricle and the superior and anterior walls of the external auditory canal are innervated by the auriculo-temporal branch of the trigeminus nerve. This nerve is a branch of the inferior division of the trigeminus, and I wish particularly to emphasize the neural connections existing between it and the geniculate ganglion through the otic ganglion and the small superficial petrosal nerve. The otic ganglion rests upon the inferior maxillary division of the fifth, just below its origin from the Gasserian. The posterior surface of the auricle receives its sensory innervation through the auricular branches of the superficial cervical plexus, which also overlap the rim and supply a posterior marginal area on its external surface. The inferior and posterior walls of the canal are supplied by the small auricular branch of the vagus, which also sends filaments to the interior of the concha. The ganglionic representations of sensation on the auricle and external auditory canal have been divided between the Gasserian in front and the second and third cervical ganglia behind. The anterior half of this region has been referred to the Gasserian and the posterior half to the cervical ganglion. An eruption of herpes in this area has been regarded as emanating from disease of one or other of these ganglia.

The error of the prevailing views will be shown by a study of the anesthesia produced by the extirpation of these ganglia for the relief of tic douloureux. In all of Krause's cases following extirpation of the Gasserian the sensation of the skin of the auricle and external auditory canal was found to be preserved and normal. In these operations during the tearing out of the ganglion, the connections existing between the fifth nerve, Meckel's ganglion, the otic ganglion, and the geniculate ganglion through the superficial petrosal nerves may be separated. This might cause confusion, by adding a geniculate anesthesia to that produced by removal of the Gasserian. This may have happened in some of Cushing's cases in which parts of the external auditory canal were found anesthetic after extirpation of the ganglion. The method of operation as practised by Frazier and

Spiller is free from this disadvantage. It consists in cutting the sensory root of the fifth on the central side of the ganglion. In such a procedure as this there is no undue tension or tearing the neural connections between the geniculate, and the second and third divisions of the fifth are not implicated. No procedure could be more exact for protecting the ganglionic area of the Gasserian. Following this operation the sensation of the auricle and auditory canal was found to be normal. The ganglionic innervation of the second and third cervical ganglia has been studied in a case of extirpation for the relief of obstinate occipito-cervical neuralgia by Harvey Cushing. In outlining the anesthesia in this case Cushing found the posterior marginal area on its external surface anesthetic. The interior of the auricle and external auditory canal had normal sensation.

If we now bring together and carefully adjust these respective areas of anesthesia, produced by extirpation of the Gasserian and the cervical ganglia, there still remains the interior of the auricle, and the external auditory canal in which sensation is preserved. In this area, I believe, it is to be found the cutaneous representation of the geniculate ganglion and its zoster zone.

It will be recalled that the peripheral innervation of this skin area is furnished by the auriculo-temporal branch of the third division of the fifth, and the auricular branch of the vagus. That these fibers do not pass through the inferior division of the fifth to the Gasserian is demonstrated by the anesthesia resulting from section of the sensory root of the fifth, this area retaining its sensation. If their afferent course is not through the trigeminus, how do they reach the brain? The relation of these sensory fibers to the geniculate ganglion is established if we accept the occurrence of geniculate herpes with a zoster zone in the auricle. So that it seems probable that these afferent fibers passing from the auricle on their way to the geniculate follow one or other of two routes, *i. e.*, from the skin of the auricle through the auriculo-temporal branch of the fifth, or the auricular branch of the vagus to the seventh nerve, the afferent fibers passing to the geniculate in the trunk of the facial nerve; or they may possibly be continued in the auriculo-temporal branch of the fifth to the otic ganglion and thence via the lesser petrosal nerve to the geniculate. Of these two routes, that through the facial is, in my opinion, the more likely one.

CLINICAL TYPES OF THE DISEASE.

Herpes Auricularis.—The simplest manifestation is to be found in the characteristic and well-known picture of herpes zoster of the auricle. There are the usual slight prodromes in the initial stage of the infection, followed by fever and mild general symptoms. Then sharp, darting pains are felt in the ear, the preherpetic pains, sometimes reaching a high degree of intensity. The skin of the ear may assume a red, swollen, somewhat erysipelatous appearance, until on the third or fourth day typical patches of herpetic vesicles make their appearance. These are situated in the concha, on the lobule, the tragus, the marginal portion of the auricle (helix and antihelix), and within the auditory canal, indeed, as rarely happens, on the *membrana tympani* itself. With the appearance of the eruption the acute pains usually subside, the ear still remaining swollen and tender.

At this stage the orifice of the external auditory canal may become constricted by the swollen soft parts, so as to interfere with the proper drainage and cleansing of the canal. The defect in hearing which may result from this temporary occlusion of the meatus, is purely mechanical and is not in any sense related to the disturbances of audition which accompany another group of cases and which is dependent upon involvement of the auditory nerve. In a few days the vesicles desiccate, the swelling and edema of the parts subside until at the end of a fortnight only a few scattered zoster scars remain to tell the tale. The sensory symptoms may, however, persist for a considerable time; burning pains, itching, paresthesia with impairment of the cutaneous sensation of the parts. In old people more especially the sharp neuralgic pains in the ear, the post-herpetic pains, may persist for a considerable time. (Herpetic otalgia.)

In this class of cases it will be observed that the herpetic pains and the herpetic eruption are localized within that skin area which retains its sensation after extirpation of the Gasserian and the second and third cervical ganglia. It was this area which I assigned to the geniculate ganglion as its cutaneous representation and zoster zone.

Remarks.—Idiopathic herpes zoster of the auricle has long been a recognized manifestation of zona. It is the herpes auricularis and herpes oticus of systematic writers. Dr. Anstie who was personally afflicted with the disease gave a very vivid de-

scription of his own case in "The Practitioner" of 1871. This localization of zoster has always been regarded as belonging to the trigeminal area, and due to disease of this nerve or its ganglion. If the observer favored the neuritic theory of herpes zoster, the skin lesions on the auricle were ascribed to a neuritis of the auriculo-temporal branch of the fifth nerve; if the ganglionic theory was accepted, the lesion was placed in the Gasserian. Some authors also speak of the auricular branches of the cervical nerves as playing a rôle in aural herpes, but no mention is made of the geniculate ganglion and its possible relation to this affection.

Compared with other manifestations of zona, the ear is an infrequent localization. Gruber records five typical cases as occurring in a series of 20,000 cases of ear disease.

To determine, if possible, the relative frequency of these cases, I examined the annual reports of several of our large hospitals for the eye and ear, with rather varying results. The total number of cases recorded is surprisingly small, so small indeed that it seems very possible that the affection not infrequently escapes recognition. It may be that when seen in the early stage of intense inflammation cases are regarded as perichondritis or inflammation of the auricle, or when seen later after dessication of the vesicles, as cases of eczema of the auricle. In the Manhattan Eye and Ear Dispensary during the past ten years, with a total of 47,600 cases, the diagnosis herpes of the auricle was made in only two cases. In the Brooklyn Eye and Ear Hospital, during the past five years, with a total of 15,000 cases, the diagnosis was made but once. The New York Eye and Ear Infirmary averages at the present time 10,000 out-patients a year, and is one of the largest institutions of its kind in the world. During the past twenty-three years this diagnosis was recorded but six times. The reports of the Massachusetts Eye and Ear Infirmary show a much larger proportion of these cases. In the past ten years with a total of 65,000 cases, the diagnosis was made 33 times. In these tabulations it was not possible to determine whether the cases were of the true infectious type, or merely of secondary origin, but the infrequency with which the diagnosis was made is worthy of note.

Herpes Auricularis with Facial Palsy.—In this manifestation of the affection, there is superadded to the herpes auricularis, as just described a peripheral facial palsy, which appears on the

same side as the zoster. The time of the appearance of this palsy varies, coming on in some cases simultaneously with the eruption, in others it may be delayed a week or even longer. In the majority of instances it appears on the second or third day. Too much stress should not be given to the patient's statements in this respect as the onset is often insidious and unobserved.

The paralysis is complete and involves all three branches of the nerve, and has certain peculiarities. A conspicuous feature is the frequent evanescence of the symptom, evidences of paralysis lasting only a few days or a fortnight. Many of the palsies clear up within three weeks or a month. There still remains, however, a large group of cases in which the palsy is of a severe type, reactions of degeneration persisting for a long time, leaving permanent weakness and contractures of the face. It is also a striking fact that in an unusually large number of these cases the sense of taste is lost or altered. This is not surprising when one considers that the seat of the lesion is in the geniculate, a level where the taste fibers are still coursing with the facial.

I would explain the involvement of the nerve in this group of cases by the pressure of an inflamed and swollen ganglion or by the direct extension of the inflammation to the sheath and connective tissue structures of the nerve. In light palsies probably inflammatory edema and pressure are the factors at play, whereas in the more severe forms inflammation and structural changes probably take place.

Remarks.—As has already been emphasized, a similar palsy may complicate herpes facialis and herpes occipito-collaris. I would explain the occurrence of the palsy in such cases by an herpetic inflammation of the geniculate ganglion, based on the well recognized tendency of this affection to produce inflammatory changes in a series of spinal ganglia. The Gasserian, geniculate and upper cervical ganglia constitute such a serial chain.

These cases of facial palsy complicating herpes of the ear, face, and neck, have long been the subject of study and controversy.

The old theories as to the origin of these palsies are as follows: The prevailing opinion is that the same exposure to cold produces both the herpes and the palsy, in which case the latter is regarded as rheumatic in nature, the common form of Bell's palsy. Another favorite theory was based on the infectious origin, the poison or

toxin concerned in herpes zoster also producing a neuritis of toxic origin. A somewhat fantastic hypothesis which found great favor with certain observers was the following: The herpetic inflammation is supposed to have extended along the peripheral filaments of the trifacial nerve, this nerve having numerous points of inosculation with the terminals of the facial. The inflammatory process then passes by continuity of structure, directly from the peripheral filaments of the trifacial to the termination of the facial, in this way producing an ascending neuritis.

Herpes Auricularis with Facial Palsy and Auditory Symptoms.
—This is the most interesting as well as the severest type of the affection. In this group to the herpetic eruption on the ear, face or neck and facial palsy, are added symptoms pointing to involvement of the auditory nerve. The proximity of the terminal divisions of the auditory nerve to the facial and its ganglia, the common sheath and narrow osseous canal in which they lie would render such an auditory complication not only possible but probable. Contributing factors may be severe forms of the inflammation or certain anatomical peculiarities such as a large ganglion or a narrow bony canal.

The auditory symptoms may be both irritative and paralytic in character and make their appearance about the same time as the facial palsy. First there is tinnitus aurium followed by progressive diminution of hearing. In the more severe cases the symptoms of Ménière's disease are also present. Disturbances of equilibrium, vertigo, nausea and vomiting, nystagmus. In the course of a few weeks the acute symptoms subside, the vertigo and disturbances of the gait and equilibrium disappear, but the tinnitus often persists for a considerable time and the hearing may be permanently impaired.

Remarks.—In this group of cases as in that previously described the auditory symptoms may complicate herpes on the neck and face as well as on the auricle. In my series of 60 cases, auditory symptoms of various degrees of severity occurred in 19 cases. Of this number the zoster was in the occipito-cervical distribution in 9 cases, on the face in 4 cases, and on the auricle and auditory canal in 6.

The uncertainty which has attended the classification of this auditory group of cases and the doubtful nature of the affection, may be gathered from a perusal of the titles of the more important com-

munications. "Ueber ein Fall von gleichseitigen, akut aufgetretene Erkrankung des Acusticus, Facialis und Trigemini" (Kaufmann, 1896).—"Ueber Polyneuritis Cerebralis ménièriformis" (Frankl-Hochwart, 1899, and Berger, 1905).—"Zur Lehre von der peripherischen Facialis Lähmung" (Hoffmann, 1899).—"Beitrag zur Casuistik der multiplen Hirn Nerven Erkrankung" (Hammerschlag, 1898).—"Herpes Zoster Oticus" (Korner, 1904).—"Trouble Auditive dans le Zona" (Lannois, 1904).

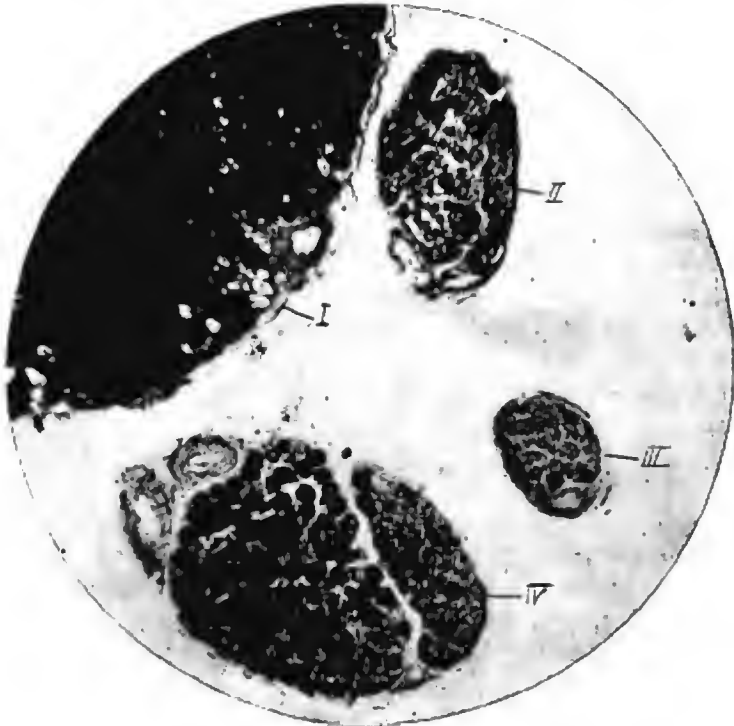


Fig. 5.
Osmic Acid Preparation, Counterstained with Rubin. I. Facial Nerve.
II., III., IV. Bundles of the Nerve of Wrisberg, Showing
Loss of Nerve Fibers and Sclerosis.

Pathological Evidence.—Recorded below under Case II is the pathological report of a case of herpes occipito-collaris in which a complete facial palsy supervened on the fourth day. There were no symptoms referable to the auditory nerve. Evidences of facial paralysis and objective sensory disturbances in the occipito-cervical region were still present at the time of death,

which occurred 87 days after the onset of the disease. Corresponding to the cervical distribution of the herpes, old inflammatory changes were found in the tip of the third cervical ganglion, with loss of nerve fibers and islets of sclerosis in the corresponding posterior root of the spinal cord. These could be traced through the 1st, 2d and 3d cervical segments, with evidences of myelin degeneration (granule cells and myelin droplets) in that



Fig. 6.

Marchi Method Intra-Medullary Degenerations in the Medial Root of the Acoustic. Entrance of the Nerve of Wrisberg.

portion of the posterior column, immediately adjacent to the posterior horns. Evidences of regeneration were also found in the branches of the superficial cervical plexus. Such pathological changes both in character and distribution are in accord with the findings in similar cases.

It is, however, to the facial nerve that I would particularly direct attention. The facial nerve, including the nerve of Wrisberg, from its exit at the medulla to its entrance at the internal

auditory canal, was treated by the osmic acid method and cut in transverse sections. By this method the nerve of Wrisberg was found to have lost a large number of its nerve fibers, with a compensatory increase of connective tissue. (See Fig. 5.) Fortunately that portion of the medulla which was treated by the Marchi method corresponded to the roots of the facial, auditory and nerve of Wrisberg, all of these structures taking their origin at the same level.

The nerve of Wrisberg (*pars intermedia*) lies between the origin of the other two nerves, sometimes it joins one, sometimes the other, as it enters the substance of the medulla. Sections through this level show distinct evidences of degeneration (myelin droplets and granule cells) along the course of the internal root of the auditory nerve, after its entrance into the medulla. See Fig. 6. In other words, we find in the nerve of Wrisberg, which is the sensory root of the 7th and having its trophic centre in the geniculate ganglion, the same extra- and intra-medullary changes as were found in the spinal cord and posterior nerve root corresponding to the 3d cervical ganglia.

Unfortunately that portion of the facial nerve removed and which was supposed to contain the intumescencia ganglioformis consisted only of membrane, so that the changes in the ganglion itself cannot be given. But even in the absence of the geniculate ganglion, the existence of well-markd degenerations in the nerve of Wrisberg and its intrabulbar root is sufficient proof that this structure was involved.

CASE I. *Herpes facialis and occipito-cervicalis with facial palsy of short duration.*

A woman, aged 66, on March 20, 1904, was exposed for one hour to a sharp cold wind. It was snowing at the time and the effects of the intensely cutting cold were keenly felt on the left side of the face and neck. Two days later sharp darting pains and tingling sensations developed in the left face, neck and occipital regions. These pains were soon followed by an eruption of herpes in the same distribution. Patches of vesicles were sparsely scattered over the skin area of all three branches of the trigeminal nerve, as well as in the occipital and cervical regions. The darting pains continued after the development of the eruption, until seven days after exposure and five days after the appearance of the vesicles, a complete left facial palsy was observed on awaking in the morning.

I saw the patient April 3, 1904, with Dr. Robert Denniston of Dobb's Ferry. At the time there was total paralysis of the left facial nerve in all its branches, with considerable sagging of the parts, lachrymation and dribbling of saliva from the corner of the mouth. Pressure over the 7th nerve in front of the ear caused pain. There were no demonstrable objective sensory disturbances of the left face or neck, and no tender points over the foramina of exit of the trigeminus nerve. Hearing and taste were not affected. There were no general cerebral symptoms and the pupils reacted normally. The other cranial nerves as well as the motility, sensation and reflexes of the extremities were entirely normal. The urine contained a slight trace of albumin but was otherwise negative. Heart sounds of good quality, no murmurs. One of the superficial cervical glands on the left side is slightly enlarged.

The sharp shooting pains continued for a week from this date, coming on usually at 1 A.M. and lasting 3 or 4 hours, and were very severe. They diminished in their intensity during the next fortnight and soon after disappeared. Within one month after the onset of the facial paralysis all trace of it had disappeared, and the patient has since enjoyed her usual robust health.

CASE II. *Herpes occipito-cervicalis with severe facial palsy Autopsy and Histological Examination.*

The patient, admitted to the City Hospital February 15, 1905, was 48 years of age and a laborer. Periodic drinker. No venereal infections. The onset of the disease took place November 26, 1904, with sharp stabbing pains in the distribution of the right occipitalis major and immediately behind and in the right ear. With the sharp lancinating pains there was also present a burning sensation on the right side of the neck. These prodromal pains continued about four days and were followed by a vesicular eruption on the right side of the neck and the lower portion of the face above the ramus of the jaw. On the 3d of December, three days after the outbreak of the herpes a right facial paralysis was first observed. The vesicles dried up leaving many small pigmented scars. Paresthesias and burning sensations persisted with occasional sharp darting pains in the affected area.

Status Praesens, February 18, 1905.—Complete right 7th paralysis of the peripheral type. Behind the right ear, along the ramus of the inferior maxilla and on the right side of the neck are scattered, pigmented post-herpetic scars. These are in the distribution of the 2d and 3d cervical segments. (*Herpes occipito-collaris*.) In this same area, sensations of touch, pain and temperature are diminished, especially over the angle of the jaw. Burning sensations and sharp neuralgic pains still persist in the scarred area. Taste and hearing are unaffected. The other cranial nerves, the pupillary and tendon reflexes are normal. Urine normal.

Electrical.—To Faradism there is no response of the facial muscles on the paralyzed side when stimulated through the nerve.

Directly applied to the muscles of the face the response is slow and very much diminished.

On March 12, 1905, developed fever with evidences of pulmonary consolidation of the upper and middle lobes of the right lung. Died March 26, 1905, at 5 P.M. Clinical diagnosis, tuberculous pneumonia.

Autopsy, March 28, 1905, at 3 P.M. A complete autopsy was performed by Dr. Oertel, pathologist to the City Hospital. The right lung was found to be the seat of an extensive tuberculous pneumonia. Gross examination of the brain and spinal cord was negative. Some of the cervical and dorsal spinal ganglia, branches of the superficial cervical plexus at its emergence from behind the sterno-cleido-mastoid muscle were removed for histological examination. The entire facial nerve from its exit at the medulla to its entrance at the porus acusticus, the facial and its geniculate ganglion in the Fallopiian canal, both Gasserian ganglia and portions of the *pes anserinus* of the facial were removed. The methods used were the Nissl, Osmic acid, Marchi-hematoxylin and eosin, Van Gieson and Weigert.

The Facial Nerve.—Teased osmicised preparations of the *pes anserinus* show the presence of numerous fine pale fibers, with rosary-like nodulations and swellings of the myelin sheath. In many other fibers the myelin covering is thin and poorly stained (pale), showing intervals and interruptions in its continuity. There are no myelin droplets or granule cells and the whole picture is regenerative rather than degenerative. The tissue removed from the Fallopiian canal and presumably consisting of the *intumescentia gangliiformis*, unfortunately did not contain this organ, so that a microscopical study of the geniculate was not possible.

The whole trunk of the facial and including the nerve of Wrisberg from its exit at the medulla to its entrance into the auditory canal was treated by the osmic acid method. Transverse sections were then made and counter-stained with acid-rubin. By this method the fibers of the facial nerve proper were found normal. In the nerve of Wrisberg, however, there was demonstrated a very distinct and well marked loss of nerve fibers with a resulting sclerosis and increase of connective tissue. See Fig. 5.

Medulla Oblongata and Pons.—The cells of the facial nucleus on the affected side under a low power are smaller, paler and more rounded than normal, with absence or only slight indications of the tigroid appearance of the Nissl bodies. Under a high power the nucleolus is but faintly stained, and the nucleus is small, irregular in outline and shrunken in appearance. In many cells the nucleus shows a partial or complete dislocation to the periphery. The Nissl bodies are broken up, the cell body presenting a finely granular appearance. In some cells there is the typical

powdery appearance of axonal degeneration. The cell body is small, rounded and the processes broken off. The quantity and quality of the cell pigment does not seem to vary in the two sides. By the Weigert method the ascending root of the facial and the root fibers in the pons show no variation on the two sides.

Transverse sections of the medulla at the exit of the facial, the nerve of Wrisberg and the acoustic, show distinct evidences of old myelin degenerations, granule cells and myelin droplets in and along the course of the median root of the auditory nerve (Fig. 6). The root of the facial and the external root of the auditory are free from such evidences of degeneration.

Cord and Nerve Roots.—The examination of the 1st, 2d, 3d, and 4th cervical nerve roots on the affected side, shows distinct evidences of old degenerations in the posterior root of the 3d cervical segment. Delicate islets of sclerosis are demonstrable. These are quite destitute of nerve elements or contain only naked and swollen axis cylinders. No remnants of myelin degeneration were present in the nerve roots. The central tip only of the right 3d cervical ganglion was removed with the attached roots which showed some thickening and proliferation of the connective tissue of the sheath on its internal surface. In the spinal cord distinct evidences of old myelin degeneration, myelin fragments, droplets and granule cells, were found scattered along the mesial side of the posterior horn and the adjacent white substance. These evidences of degeneration could be readily traced through the 1st, 2d and 3d cervical segments. The right Gasserian ganglion showed no evidences of inflammation or degeneration. The teased osmic preparations of the branches of the superficial cervical plexus, show the same regenerative changes as were described in the *pes anserinus* of the facial nerve.

Concluding Remarks.—Briefly summarized my conclusions are as follows: The facial nerve like the trifacial is a mixed nerve. Its sensory ganglion is the geniculate. The motor root of the geniculate is the facial nerve proper and its sensory root is the nerve of Wrisberg. Below the ganglion the peripheral divisions are the facial nerve proper, the great and lesser superficial petrosal nerves, the external petrosal and the chorda tympani. This ganglion is of the spinal ganglion type and therefore in common with other ganglia of this type, comes within the realm of true herpes zoster.

The zoster zone for the geniculate is found in the interior of the auricle and in the external auditory canal.

The only neural connections existing between the geniculate ganglion and this cutaneous area are the auriculo-temporal branch

of the 5th through the medium of the small superficial petrosal nerve and otic ganglion and through the facial nerve proper. One or both of these routes may be taken by the afferent fibers from the auricle in their central course; in my opinion the facial route is the more probable one.

The ear-zone of the geniculate is intercalated between the zone for the Gasserian in front and the cervical ganglion behind, so that the zoster zones of the cephalic extremity are represented by the Gasserian (face and forehead), the geniculate (ear), the 2d and 3d cervical ganglia (occiput and neck). The zoster inflammations while attacking chiefly one, not infrequently involve more than one ganglion, milder changes showing in a series of ganglia above and below, diminishing in intensity from the central focus. For the same reason zoster in any of the zones of the cephalic extremity, may be accompanied by inflammatory reaction in the other ganglia of this group.

The pathology underlying the affection is the specific hemorrhagic inflammation of the ganglion as found in zona. As the geniculate is lodged in a narrow bony canal and stands in close relation to the 7th and 8th nerves, the characteristic syndrome is produced.

This syndrome may be divided into three clinical groups:

1. Herpes zoster auricularis.
2. Herpes zoster in any of the zoster zones of the cephalic extremity (Herpes auricularis, herpes facialis, and herpes occipitocollaris) with facial palsy.
3. Herpes zoster of the cephalic extremity with facial palsy and auditory symptoms (Tinnitus, deafness, vertigo, vomiting, nystagmus and disturbances of equilibrium).

In the foregoing pages I have endeavored to outline as briefly as possible the anatomical, pathological and clinical facts upon which I have based the syndrome. For the sake of conciseness and clearness, I have eliminated as far as possible all material not absolutely necessary for a convincing argument. For the same reason but few direct personal references have been made to the work of the long list of able investigators, who were my predecessors in this field. In a subsequent communication I hope to be able to give the subject broader and more elaborate treatment.

The abundant literature which has grown up in relation to

this subject will be appreciated on scanning the bibliography which is appended in full.

NEURALGIC AFFECTIONS OF THE GENICULATE GANGLION AND ITS DIVISIONS. (Otalgia.) A Preliminary Report.

As the facial is a mixed nerve, having a sensory-ganglion, a cutaneous representation and zoster zone, the thought naturally arises, may it not be the seat of purely functional derangements similar to those occurring in the trigeminal area. May there not exist otalgia referable to the sensory mechanism of the facial, as there is prosopalgia originating in the sensory mechanism of the trifacial.

That herpes zoster of the auricle may be followed by severe neuralgic pains in the ear is well known. These herpetic otalgias are secondary, and in accordance with my views on this subject are dependent upon organic changes in the geniculate ganglion of the facial nerve.

On considering the extreme sensitiveness and delicacy of the organ of hearing, the high degree of its innervation, its exposed situation through the external auditory canal, the predisposition of such a mechanism to neuralgic disturbances would seem very probable.

This is the case. Otalgia, earache of non-inflammatory origin in its various forms is by no means an uncommon affection.

I would here mention briefly the branches and neural connections of the facial nerve and ganglion.

I. The ganglion stands in relation to the interior of the auricle and external auditory canal, its zoster zone (through the medium of the facial nerve or the small superficial petrosal nerve?).

II. The ganglion is intimately connected with the tympanic plexus. This is effected through the medium of the small and large deep petrosal nerves which arise in the tympanic plexus and join the small and large superficial petrosal nerves on their way to the geniculate.

III. The ganglion has also direct relations with the 2d and 3d divisions of the 5th, through the medium of the great and small superficial petrosal nerves which pass to Meckel's and the Otic ganglia respectively.

IV. It has reflex connections with the glosso-pharyngeal

nerve through Jacobson nerve, which enters into the formation of the tympanic plexus.

V. Another reflex connection is with the vagus through its small auricular branch. This nerve sends an ascending and descending filament to the facial as it crosses the Fallopian canal.

From these brief statements an idea may be obtained of the intimate neural relation existing between the facial nerve and ganglion and the tympanic cavity, auricle and external auditory canal; as well as the reflex neural connections with the trigeminal, glosso-pharyngeal and vagus nerves. A great many of the otalgias are of reflex origin. In these forms there occur with caries of the teeth and ulcerative affections of the tongue, pharynx and larynx, neuralgic pains, localized in the ear. These cases are quite common and the relation between the nerves supplying the region of the mouth and naso-pharynx and larynx with sensation and the tympanic cavity and auricle furnish an anatomical basis for the reflected pain.

The primary otalgia, idiopathic neuralgic affections of the ear, are recognized by nearly all systematic writers. This group of cases, however, as is the case with auricular herpes is divided between the trigeminal and occipito-cervical nerves. If the pain predominates in the anterior half of the auricle, they are usually relegated to the trigeminal, or if in the posterior to the occipito-cervical neuralgia. I believe, however, that there exists an otalgia, an independent primary and idiopathic affection of the sensory system of the facial nerve, and that this group will occupy the same place and have the same significance as the other time-honored clinical group of neuralgias.

BIBLIOGRAPHY.

ANATOMY AND PATHOLOGY.

- Armand-Delille and Camus. (Autopsy). *Neur. Central.*, 1903, p. 144.
 Armand-Delille and Camus. *Soc. de Neur. de Paris*, February, 1903.
 Bärensprung. *Charité Annalen*, Vol. X.
 Birmingham. *The Nerve of Wrisberg. Journ. of Anat. and Phys.*, 1895.
 Cushing. *A Study of the Trigeminal Field. Johns Hopkins Bull.*, July, 1904.
 Cushing. *Journ. Amer. Med. Assoc.*, 1905.
 Dixon. *The Course of the Taste Fibers. Edin. Med. Jour.*, 1897, June.
 Dixon. *The Sensory Distribution of the Seventh Nerve in Man. Jour. Anat. and Phys.*, Vol. 33, p. 471.
 Frazier and Spiller. *Division of Sensory Root of the Fifth for Tic Douloureux. Jour. Amer. Med. Assoc.*, 1904. *Univ. of Penna. Med. Bull.*, 1901, Vol. 24, p. 343.

- Ferguson. Exostoses with Degeneration of the Vidian Nerve. *Med. News*, 1890.
 Frühwald. The Geniculate Ganglion. *Sitzungsbericht der wien. Akad. f. Wiss.*, Vol. 74, p. 9.
 Gaskell. The Cranial Nerves. *Jour. of Physiol.*, 1889, p. 153.
 Hedinger. (Autopsy.) *Deut. Zeit. f. Nervenheil.*, Vol. 24, p. 305.
 Howard. The Pathology of Nasal and Labial Herpes (Autopsy). *Amer. Jour. Med. Sc.*, 1903.
 Krause. Die Neuralgie des Trigemini. 1896.
 Lenhossek. Gang. Geniculate und seine Verbindungen, 1894.
 Penzo. Ueber das Gang. Genic. *Anat. Anzeiger*, Vol. 8, p. 738.
 Ruge. Peripheral Distribution of Seventh in Vertebrates. *Zeit. z. Siebtz. Geburtstag. Gegenbauer*.
 Van Gehuchten. *Système Nerveux*, 1906.
 Head and Campbell. Pathology of Herpes Zoster. *Brain*, 1905.

OTALGIA.

- Eitelberg. Ein Fall von Neuralgie der Ohrmuschel. *Wien. med. Presse*, 1902, No. 26.
 Butter. A Case of Otaglia. *Canada Lancet*, 1902.
 Spira. Otaglia Nervosa. *Wien. med. Blätter*, 1901, No. 15.
 Eitelberg. Otaglia and Mastalgia. *Wien med. Blätter.*, 1901, p. 879.
 Gruber. Ein Fall von typischer Otaglia. *Monats. f. Ohrenheil.*, 1869, No. 9.
 Orne-Green. Otaglia Intermittens. *Trans. Amer. Otol. Soc.*, 1875, 7.
 Kaufmann. Otaglia. *Wien. med. Blätter.*, 1896.
 Politzer. Otaglia. *Lehrbuch*.
 Dench. Reflex Aural Symptoms Dependent Upon Dental Caries. *Dental Cosmos*, 1901.
 McBride. Aural Neuroses. *Practitioner*, August, 1898.
 Dunn. A Severe Case of Mastoid Neuralgia. *Charlotte med. Jour.*, March, 1901.
 Kretschmann. Kiefergelenk Erkrank. als Ursache der Otaglia Nervosa. *Arch. f. Ohrenheil.*, Bd. 56, 1902.
 Richards. Aural Neuralgia. *Trans. Amer. Laryng., Rhin. and Otol. Soc.*, 1905.

HERPES AURICULARIS.

- Anstie. Auricular Herpes. *The Practitioner*, 1871, Vol. 7, p. 198.
 Blake. Herpes Zoster Auricularis. *Boston Med. and Surg. Jour.*, 1877, Vol. 1.
 Gruber. Herpes Auricularis. *Monats. f. Ohrenheil.*, 1875, No. 5.
 Hasslauer. Herpes Zoster Oticus. *Deut. mil. arzt. Zeit.*, 1905, Vol. 34, p. 261.
 Burkner. Herpes Auricularis. *Lehrbuch*, p. 72.
 Gruber. Herpes Auricularis. *Lehrbuch*, 1888.
 Schwartz. Herpes Auricularis. *Lehrbuch*, 1893.
 Urbanschitsch. Herpes Auricularis. *Lehrbuch*, 1901.
 Blau. Herpes Auricularis. *Encyclop. der Ohrenheil.*
 Vail. Herpes Zoster Auris. *Laryngology and Rhinology*, 1906.
 Ladreit De Lacharriere. L'Herpes de l'Oreille. *Annal. de Mal. de l'Oreille*, 1877.
 Sommers. Aural Herpes. *Amer. Med. and Surg. Bull.*, 1896.

HERPES AND FACIAL PALSY.

- Barthelamy. *Soc. Franc. de Derm.*, 1891, p. 552.
 Besnier. (These de Paris, 1901, Gaudu).
 Coob. *Bost. Med. and Surg. Jour.*, 1869.
 Darabseth. *Lancet*, 1894, p. 1129.
 Eichhorst. *Centralb. f. Innere Med.*, 1897, No. 18.
 Ebstein. *Virchow Archiv.*, 1895, p. 512.
 Fraser. *Lancet*, 1904, Vol. 1, p. 18.
 Frich. *Monats. f. prak. Derm.*, 1898, p. 375.

- Fay. *Brit. Med. Jour.*, 1883, p. 1246.
 Gaudu. *These de Paris*, 1901.
 Greenough. *Bost. Med. and Surg. Jour.*, 1869.
 Grassmann. *Deut. Arch. f. klin. Med.*, Vol. 59, 1897.
 Hess. *Centralb. f. innere. Med.*, 1897, p. 426 (cited by Eichhorst).
 Hervormet. *Gaz. Med. de Nantes*, 1892, Oct. 12.
 Hewlett. *California State Jour. of Medicine*, 1906, p. 119.
 Letulle. (Gaudu, *These de Paris*, 1901.)
 Murphy. *Brit. Med. Jour.*, 1897.
 Montgomery. *Occident Med. Times*, 1900, Vol. 14, p. 109.
 Morrice. *St. Bartholomew's Hosp. Rep.*, Vol. 32, p. 167.
 Neilson. *Monats. f. prak. Derm.*, 1898, p. 375.
 Klippel. (Gaudu, *These de Paris*, 1901.)
 Politzer. *Lehrbuch der Ohrenheil.*, 1893, p. 167.
 Spencer. *Lancet*, 1894, p. 1447.
 Strubing. *Deut. Arch. f. klin. Med.*, 1885, p. 513.
 Testaz. (Gaudu, *These de Paris*, 1901.)
 Tomka. *Arch. f. Ohrenheil.*, 1900, p. 28.
 Tryde. *Schmidt's Jahrbuch*, 1872, s. 273.
 Truffi. *Virchow's Archiv.*, 1898.
 Truffi. *Gior. Ital. d. Mal. Ven.*, Vol. 39, p. 232.
 Rabbé. *These de Paris*, 1901, Gaudu.
 Rugani. *Bull. d. Ma. d. Orecchio.*, 1905, Vol. 23, p. 73.
 Van Someren. *Lancet*, 1895, p. 1372.
- HERPES WITH SEVENTH PALSY AND AUDITORY SYMPTOMS.
- Barnes. *Lancet*, 1902, p. 1197.
 Berger. *Neur. Central.*, 1905, p. 844.
 Busch. *Lancet*, 1902, p. 1197 (discussion).
 Cassasus. *Jour. de. Med. de Bord.*, 1906, p. 413 (two cases).
 Gibson. *Australasian Med. Gaz.*, 1895, Vol. 14, p. 181.
 Gaudu. *These de Paris*, 1901.
 Hoffmann. *Deut. Zeit. f. Nerven.*, 1894, Vol. 5.
 Hammerschlag. *Arch. f. Ohren.*, Vol. 45, p. 1, 1898.
 Hammerschlag. *Wien. med. Woch.*, 1899, No. 2.
 Hammerschlag. *Arch. f. Ohrenheil.*, 1901, p. 16.
 Kaufmann. *Zeit. f. Ohrenheil.*, 1896, p. 125.
 Kaufmann. *Arch. f. Ohren.*, Vol. 52, s. 1.
 Körner. *Münch. med. Woch.*, 1904, p. 6.
 Lannois. *Lyon medicale*, Vol. 91.
 Lannois. *Annal. de. Mal. de l'Oreille*, 1904, Septembre.
 Klippel and Aynard. *Jour. de. Practic.*, 1899, No. 15.
 Testaz. (*These de Paris*, 1901, Gaudu.)
 Voight. *St. Petersburg med. Woch.*, 1884, No. 45.